

Asymptomatic Hemangioma of the Duodenum

Tristan Thomas^{1*}, Michael Haney¹, Matthew Doepker¹

¹University of South Carolina/Palmetto Health, Columbia, SC, USA; tstepsp07@gmail.com (T.T).

Abstract: Hemangiomas of the small bowel are exceedingly rare benign tumors. When diagnosed they are found in the setting of an acute gastrointestinal bleeding, but can also be involved in intussusception, obstruction, and cause pain. There are few reports of this case overall, and incidental or asymptomatic cases are rare for adult patients. Although computed tomography with angiography or tagged red blood cell scans are pivotal for acute active bleeding, endoscopy has become pivotal in diagnosis of lesions that are quiescent. Management is also variable as endoscopy, laparoscopy, and open surgery have all been utilized with success.

Keywords: *Asymptomatic hemangioma, Rare benign tumors, Endoscopy.*

1. Introduction

Small bowel tumors are rare and clinicians generally find them when patients become symptomatic. Metastatic lesions such as melanoma have been found to outnumber primary tumors, although 47% of those primary tumors are benign [1, 2]. The most common benign histology includes adenoma, lipoma, leiomyoma, and hemangioma. Hemangiomas are vascular malformations involving the proliferation of blood vessels in the submucosa and are commonly diagnosed in infants and children. Cavernous hemangiomas present as the dominant type, but there is also multiple phlebectasia, capillary hemangioma and angiomas with gastrointestinal lesion. The incidence of hemangioma is approximately 10% of benign small bowel tumors and only 0.3% of all gastrointestinal tumors [3]. The frequency of benign small bowel tumors tends to increase from the duodenum to the ileum. In a similar pattern, most reported cases of hemangiomas have occurred in the jejunum and ileum, therefore making duodenal lesions exceedingly rare [4]. The most common symptom is gastrointestinal hemorrhage and anemia, which accounted for 73.2% of small bowel hemangioma cases. Obstructive symptoms are far less frequent, occurring at only 12.8%. Interestingly, 30% of hemangioma cases have been found to asymptomatic [5].

Much of the discussion in the literature concerning hemangiomas of the duodenum occurs primarily in case reports. Treatment strategies for patients with symptoms encompass medical intervention, endoscopic therapy and surgical resection. No established algorithm to the management of these lesions in adults exists. We will discuss a patient who presented to us with an incidental, asymptomatic hemangioma of the duodenum and review the various treatment options available in the current literature.

1.1. Case Report

An 18-year-old female was involved in a motor vehicle accident and was noted to have an obvious seatbelt sign, therefore abdominal trauma was suspected on initial assessment. The initial Computed Tomography (CT) scan revealed a lobulated mass encompassing most of the medial wall of the 1st and 2nd portion of the duodenum. The mass measured 3.4 by 2.4 cm and was associated with some scattered calcifications. The initial read favored duodenal hematoma, so she was transferred to a level one trauma center. Magnetic Retrograde Cholangiopancreatography (MRCP) revealed a sessile, polypoid mass extending from the first to third portion of the duodenum, which measured 6 cm in length (**Figure 1**). Imaging modality did not reveal any evidence of metastatic lesions or lymphadenopathy to suggest malignancy. The abdominal pain associated with the trauma resolved after 2 days, and she was soon discharged from the hospital with outpatient surgical oncology follow-up.

An endoscopic ultrasound was recommended by surgical oncology to conclusively determine if this was a traumatic hematoma or a potential malignancy. This was performed 33 days after the accident and it demonstrated a large mass containing a cluster of vessels extrinsic to the walls of the duodenal bulb. The liver, bile ducts, pancreas and regional lymph nodes appeared normal and there was no concern for malignancy.

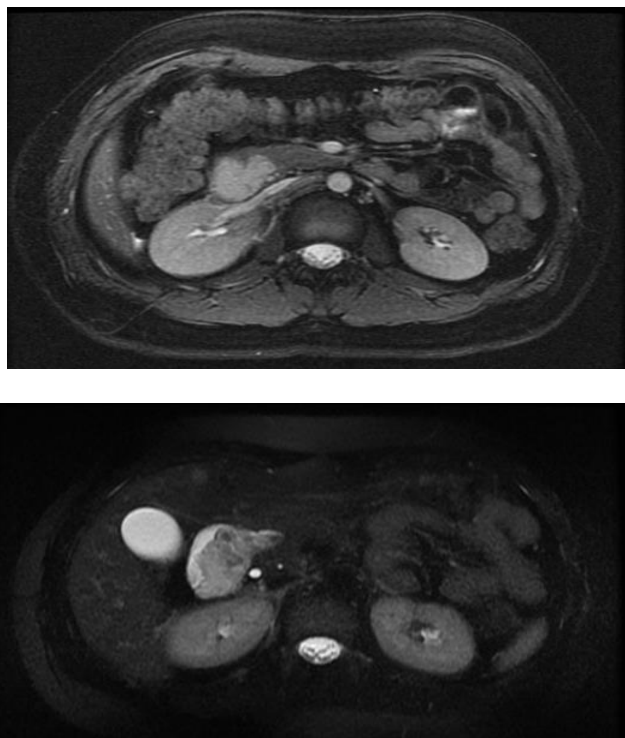


Figure 1.

The images above show a sessile polypoid mass extending from the duodenal bulb into the second and third portions of the duodenum. This is isointense to the kidney on FIESTA images (top) and slightly hyper intense on T2 weighted sequences (bottom).

Biopsies were obtained and immune-histochemical staining was consistent with a benign hemangioma, which exhibited strong expression for CD 31 but was negative for D2-40. She denied a history of anemia and her hemoglobin was normal at 12.7 g/dL. She remained asymptomatic so non-operative management with yearly surveillance was recommended.

2. Discussion

Diagnosis of these rare tumors can pose a challenge for clinicians, especially when the patient is asymptomatic. Several diagnostic modalities are available, which include video capsule endoscopy (VCE), double-balloon enteroscopy (DBE), CT scan, MRCP, CT enterography and angiography. Angiography and technetium Tc 99m red blood cell scanning is limited when there is no active bleeding [1]. CT enterography can improve sensitivity to 85-97%, but endoscopy has emerged as the preferred diagnostic modality [6]. VCE and DBE have shown the greatest impact on the diagnosis and treatment of small bowel disease in the modern era of medicine [7]. VCE can find significant lesions at any part of the small bowel and can be pivotal in the work-up of gastrointestinal hemorrhage. Flexible endoscopy and DBE also allow for tissue biopsy sampling, marking with ink tattoo and therapeutic intervention.

Medical management has been discussed in the pediatric literature available on this topic. Beta blockers and other topical agents have an established role for cutaneous hemangiomas. When beta blockers are not tolerated, prednisolone dosed at 3-10 mg/kg is provided for 6-8 weeks [8]. Interferon alpha (IFN- α) administered as a subcutaneous injection has found a role in treating steroid resistant, life threatening cavernous hemangiomas. The indications for IFN- α include life threatening lesions that are pulmonary, hepatic, and gastrointestinal and those causing consumptive coagulopathy [9]. Interventional radiology can assist utilizing embolization techniques, which rely on the rich collateralization of blood flow to this region. It is unclear if medical management or percutaneous embolization has a role in the treatment of this disease in adults.

Endoscopy has paved a new path in both the diagnosis and treatment of gastrointestinal lesions. Endoscopic Mucosal Resection (EMR) and ablative therapies have become a staple in the treatment of dysplastic lesions of the gastrointestinal tract. EMR involves injecting saline into the submucosal plane under direct endoscopic visualization, followed by snare resection of the lesion. Nishiyama et al. explored the role of EMR in the treatment of duodenal hemangiomas. They developed their own criteria based on accessibility, size of 2cm or less, and absence of large blood vessels within the lesion. Esophagogastroduodenoscopy (EGD) followed by CT angiography was performed to characterize a 2 cm lesion without large vessels along the superior duodenal angle. This was successfully resected using EMR with excellent hemostasis [10].

Although technically demanding, there has been successful laparoscopic resection of duodenal hemangioma. A few reports of hand-assisted laparoscopic resections are documented but have been faulted for poor visualization. Kanaji et al. reported one of the few totally laparoscopic resections while employing endoscopy, termed as laparoscopic and endoscopic cooperative surgery. The author documented the successful resection of a 2 cm hemangioma found in the third portion of the duodenum and the mid jejunum. The two key portions of the duodenal resection are the laparoscopic Kocher maneuver and the EGD to visualize the lesion from the intraluminal side. The laparo-endoscopic view enabled resection of the duodenal tumor with suitable margins through visualization of both the mucosal and serosal sides of the tumor [3].

Open surgery is a preferred approach over laparoscopy when patients cannot tolerate pneumo-insufflation, have significant adhesive disease or have acute bleeding with hemodynamic instability. This approach can be augmented with intraoperative endoscopy, generally performed for those with gastrointestinal bleeding and no identifiable source as a last effort. The current shift towards minimally invasive techniques mentioned previously has been explored to circumvent the increased hospital stay, postoperative ileus and morbidity of open surgery [10].

3. Conclusion

A hemangioma of the duodenum was incidentally discovered on CT, which has remained asymptomatic to date. The management plan consists of yearly surveillance with MRI imaging. Multiple therapeutic options have been discussed in this article. If our patient becomes clinically symptomatic, she may be a candidate for endoscopic or surgical resection. A more aggressive approach such as pancreaticoduodenectomy may be necessary if malignancy becomes a concern. Future management of these tumors will include optimization of surveillance with continued improvements in minimally invasive resection leading to decreased morbidity with improvement in quality of life.

References

- [1] J. W. Harris and E. B. Mark, *Small intestine. Sabiston textbook of surgery, edited by courtney Townsend*, 20th ed. 2006.
- [2] J. H. Eckel, "Primary tumors of the jejunum and ileum," *Surgery*, vol. 23, pp. 467-475, 1948.
- [3] S. Kanaji et al., "Laparoscopic partial resection for hemangioma in the third portion of the duodenum," *World journal of gastroenterology: WJG*, vol. 20, no. 34, p. 12341, 2014.
- [4] J. M. Wilson, D. Melvin, G. Gray, and B. Thorbjarnarson, "Benign small bowel tumor," *Annals of Surgery*, vol. 181, no. 2, pp. 247-250, 1975.
- [5] P. Nader and F. Margolin, "Hemangioma causing gastrointestinal bleeding: Case report and review of the literature," *American Journal of Diseases of Children*, vol. 111, no. 2, pp. 215-222, 1966.
- [6] F. Pilleul, M. Penigaud, L. Milot, J.-C. Saurin, J.-A. Chayvialle, and P.-J. Valette, "Possible small-bowel neoplasms: Contrast-enhanced and water-enhanced multidetector CT enteroclysis," *Radiology*, vol. 241, no. 3, pp. 796-801, 2006. <https://doi.org/10.1148/radiol.2413051429>
- [7] N. Takase et al., "Preoperative detection and localization of small bowel hemangioma: Two case reports," *World Journal of Gastroenterology*, vol. 23, no. 20, p. 3752, 2017. <https://doi.org/10.3748/wjg.v23.i20.3752>
- [8] A. Chattopadhyay, V. Kumar, M. Maruliah, and P. Rao, "Duodenojejunal obstruction by a hemangioma," *Pediatric Surgery International*, vol. 18, pp. 501-502, 2002. <https://doi.org/10.1007/s00383-002-0838-8>
- [9] R. A. B. Ezekowitz, J. B. Mulliken, and J. Folkman, "Interferon alfa-2a therapy for life-threatening hemangiomas of infancy," *New England Journal of Medicine*, vol. 326, no. 22, pp. 1456-1463, 1992. [https://doi.org/10.1016/0020-7292\(93\)90812-b](https://doi.org/10.1016/0020-7292(93)90812-b)
- [10] N. Nishiyama et al., "Bleeding duodenal hemangioma: Morphological changes and endoscopic mucosal resection," *World journal of Gastroenterology: WJG*, vol. 18, no. 22, pp. 2872-2876, 2012.